



Cytogenetic Findings in Regressing Skin Lesions of Lymphomatoid Papulosis

Katharina Peters, Joan H. M. Knoll, and Marshall E. Kadin

ABSTRACT: In this report, we present the cytogenetic findings in an adult female patient with lymphomatoid papulosis (LyP) type A, a cutaneous lymphoproliferative disorder with possible progression to lymphoma. Karyotyping of the CD30+ atypical lymphoid cells revealed numerical and structural aberrations. Trisomy 7, a common finding in hematologic disorders such as adult T-cell leukemia and non-Hodgkin lymphomas, was detected. Additionally, a breakpoint was found at 10q24 in the region of the TCL3 oncogene. These results contrast with cells of a young female patient (age 3) with a type A LyP, which showed a normal karyotype as well as cells of a male adult with type B LyP. None of the cases showed the t(2;5)p(23;q35) common in CD30+ anaplastic large cell lymphomas, which can closely resemble LyP. Our findings are discussed in the context of the literature concerning the histology, immunophenotyping, and cytogenetics of LyP. Together the results suggest different steps in the development of LyP and distinct forms of this one disease.

INTRODUCTION

Lymphomatoid papulosis (LyP) is a cutaneous lymphoproliferative disorder which resembles malignant lymphoma as first described by Macaulay [1]. The lesions, which are papules and nodules, are clinically benign and spontaneous regression is characteristic. However, development of malignant lymphoma occurs in 10–20% of patients. Histologically, a variable number of large atypical lymphoid cells can be found. LyP has been divided into types A and B, with type A cells resembling Reed-Sternberg cells of Hodgkin's disease (HD) and type B containing smaller cells with cerebriform nuclei as seen in mycosis fungoides. These atypical cells have the phenotype of activated helper T-cells (CD4+) expressing HD-associated antigen (CD30) [2]. Chromosomal studies of lymphomatoid papulosis are few [3–5]. DNA histograms show predominantly diploid cells in type B LyP and aneuploid cells in type A LyP [6, 7]. We describe the cytogenetic findings in three cases of lymphomatoid papulosis.

MATERIALS AND METHODS

Excisional skin biopsy specimens were obtained from three patients with LyP uncomplicated by lymphoma, and cultured in RPMI 1640 containing 25% human plasma, 1% penicillin/streptomycin, and 2000 μ /ml IL-2 using 24 well-plates.

Cytospins from the tissue cultures showed reactivity of atypical cells with antibodies against Ki-1 (CD30), the IL-2-receptor (CD25), T-cell antigens Leu3a (CD4), Leu4(CD3), Leu5(CD2), Leu1(CD5), and leukocyte common antigen (CD45). Cells were cultured for 3–8 weeks prior to harvest. After transfer to 25-cm² culture flasks, cells were harvested using 0.1 μ g/ml Colcemid for 30 minutes. The cells were incubated in 75 mM KCl for 22 minutes and fixed with acetic acid:methanol 1:4. Air-dried slides were incubated overnight at 80°C and banded with a G-banding protocol using trypsin and Giemsa stain [8]. To exclude any abnormalities in the constitutional karyotype, PHA-stimulated lymphocytes of patient 1 served as a control.

RESULTS

Case 1

Biopsy of a skin lesion on the left thigh was taken from a female patient, age 40, with a history of self-healing eruptions. Histopathologically the sections showed a moderate number of mitoses and large atypical cells; therefore, this case was classified type A LyP. Staining with monoclonal antibodies showed reactivity of atypical cells with Ki-1 (CD30), IL-2 receptor (CD25), LCA (CD45), CD4, and CD11c. Cytogenetic analysis revealed a complex karyotype with structural and numerical aberrations. Thirty-five metaphases were analyzed. The karyotype was 47,XX,+7,del(10)(q24),add(12)(p13),-19,+mar/48,XX,+7,del(10)(q24),add(12)(p13),+mar.

Case 2

Biopsy of a cutaneous nodule on the left thigh was taken from

From the Department of Pathology, Beth Israel Hospital, Boston, Massachusetts.

Address reprint requests to: Marshall E. Kadin, Department of Pathology, Beth Israel Hospital, 330 Brookline Avenue, Boston, MA 02215.

Received May 11, 1994; accepted July 8, 1994.

a nodule of a 3-year-old girl with a 1.5-year history of spontaneously regressing lesions on the legs. Histopathologic examination showed changes consistent with LyP type A. Immunophenotyping of the atypical cells revealed the same pattern as Case 1 without expression of CD11c. Fifty metaphases were analyzed, 40 of which revealed a normal female karyotype, (46,XX). Ten cells showed random chromosomal losses.

Case 3

A biopsy was taken from a skin lesion of 3 weeks' duration located on the left forearm of a 26-year-old male patient. The lesion was classified as type B LyP. The cells were reactive with antibodies CD30, CD45, CD4, CD3, and CD25. Thirty-three metaphases were analyzed; 25 revealed a normal male karyotype (46,XY), and eight showed random chromosomal losses. The results are summarized in Table 1.

DISCUSSION

Lymphomatoid papulosis (LyP) is a cutaneous lymphoproliferative disease which can be divided histopathologically into two types, A and B. Its clinical course is usually benign. Nevertheless, subsequent systemic lymphomas such as cutaneous T-cell lymphomas and Hodgkin's disease have been reported [9–13]. A prediction of which patients might develop malignant lymphoma cannot be made by pathologic examination. However, a recent review indicates that patients with type B LyP, comprised predominantly of diploid cells, are at low risk to develop lymphoma [10].

Our study revealed an aneuploid karyotype in the atypical cells obtained from the skin lesion of an adult patient with type A LyP, including structural and numerical changes. Trisomy 7 was detected. Structural aberrations of chromosomes 10 and 12, as well as an unidentified marker, were also seen. Only single cell aberrations, but no clonal chromosomal changes, could be found in the cells of the young child with type A LyP (Case 2) as well as in the cells from the adult male with type B LyP (Case 3). The lack of chromosome abnormalities in these patients may be due to the early stage of disease in the child with LyP type A and the usual diploid DNA content and low association of lymphoma with type B LyP [5, 6, 10]. These normal findings also could be due to preferential growth of normal cells, particularly tumor-infiltrating lymphocytes. We have attempted to avoid this possibility by selecting cultures for study which have

the cytomorphology and immunophenotype of the atypical cells in LyP.

Cytogenetic analyses of four other cases of LyP have been reported [3–5], as well as two cases of cutaneous T-cell lymphoma associated with LyP [11, 12]. Espinoza et al. [3] reported an abnormal hypertetraploid karyotype with 94 chromosomes, but was unable to identify the numerical or structural aberrations. The histologic description of this case suggests that this patient had type A LyP. Parks et al. [4] described a 47,XY, + 21,t(18;?)(p13;?) karyotype in another case of type A LyP, and a normal female karyotype in a patient with LyP type B. Whang-Peng et al. [5] examined cells from a patient with LyP of unknown type as a control for studies of cutaneous T-cell lymphomas and found a normal chromosomal pattern.

The finding of trisomy 7 in one patient with LyP type A is interesting. This numerical aberration is often reported in hematologic disorders such as adult T-cell lymphoma [14], non-Hodgkin lymphomas [15], and high-grade peripheral T-cell lymphomas [16]. Trisomy 7 has also been reported in subpopulations of tumor-infiltrating lymphocytes in kidney tumors and in the tissue surrounding the kidney [17]. However, this possibility is excluded in our case since the same cell contained multiple other chromosome abnormalities (Fig. 1). An abundant expression of T-cell growth factor receptor, as described in T-cell leukemias [18], or of the beta- or gamma-chain of the T-cell receptor might be considered, although these loci were not involved in specific translocations in our cases. Involvement of chromosome bands 7q32/34 and the pericentric region of chromosome 7 has also been reported in Hodgkin's disease, which resembles type A LyP [19]. Trisomy 7 may be a common event in the development of cutaneous T-cell lymphomas, having been observed also in mycosis fungoides and the Sézary syndrome [16].

The breakpoint of 10q24 is in a region frequently affected in non-Hodgkin's lymphomas [20]. However, most abnormalities in this region have been associated with B-cell tumors. An exception is the TCL3 oncogene, which may be involved in primary chromosome changes in T-cell neoplasia [21, 22]. An altered chromosome 12 was also detected. We previously found abnormalities of chromosomes 10 and 12 in CD30+ cell lines developed from skin nodules of another LyP patient who progressed to a CD30+ cutaneous T-cell lymphoma [13]. Thus abnormalities of chromosomes 10 and 12 appear to be a feature common to LyP and certain lymphoid malignancies.

Table 1 Clinical pathology and cytogenetic results

Case	Age/sex	Histology	Immunophenotype of LyP cells	Karyotype [no. of cells]
1	40/F	type A LyP	Ki-1 (CD30) IL-2 rec. (CD25) LCA (CD45) CD4, CD2, CD5, CD11c	47,XX, + 7,del(10)(q24),add(12)(p13) - 19, + mar/48,XX, + 7,del(10)(q24), add(12)(p13), + mar[35]
2	3F	type A LyP	Ki-1 (CD30), CD25 CD4, CD2, CD5	46,XX(40)/ random losses [10]
3	26/M	type B LyP	Ki-1 (CD30) CD4, CD2, CD5, CD3, CD25	46,XY(25)/ random loses [8]

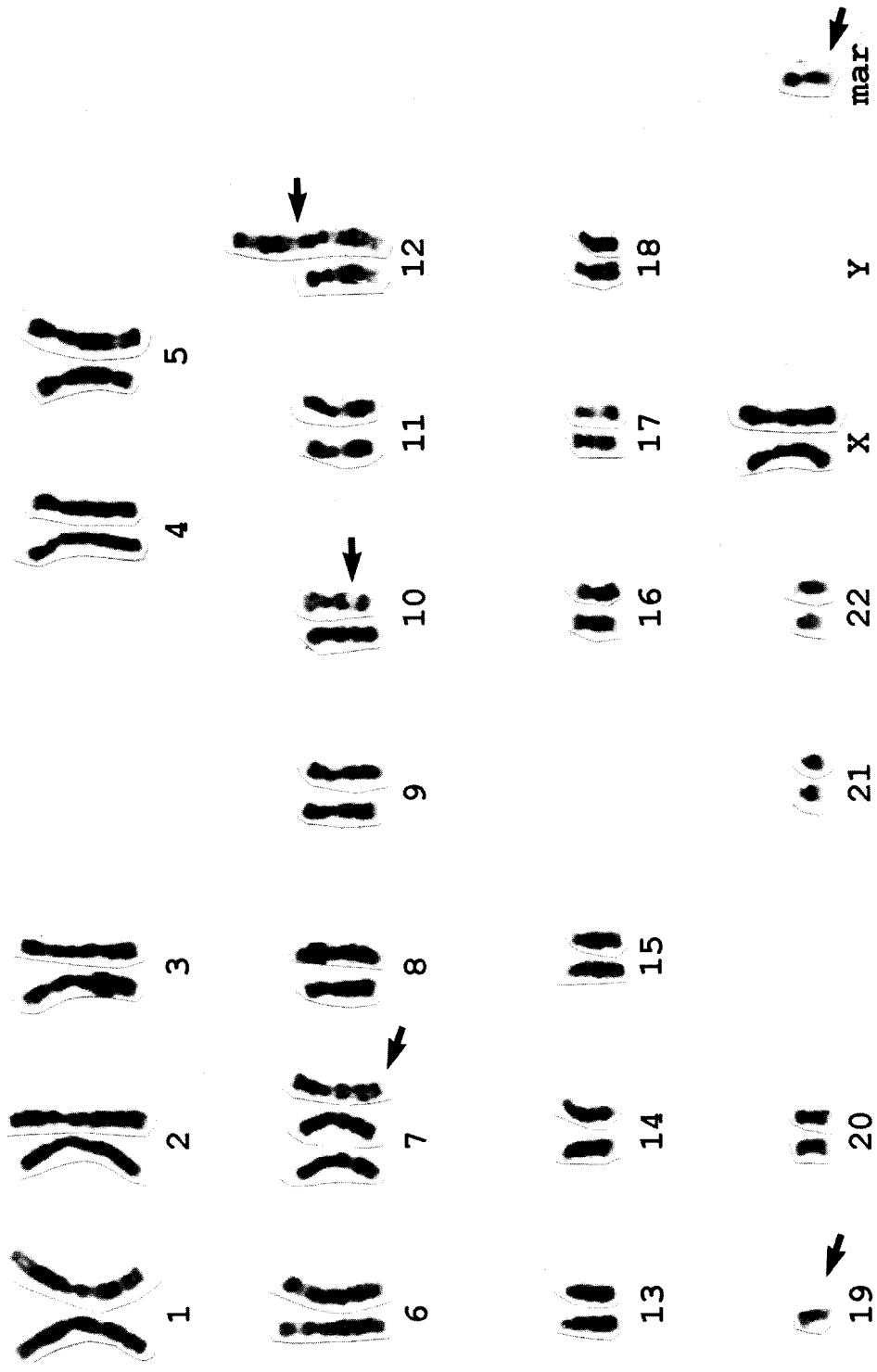


Figure 1 Karyotype of patient 1:47,XX,+7del(10)(q24),+add(12)(p13),-19,-19,+mar.

A clonal relationship between Ki-1(CD30)+ anaplastic large cell lymphoma and LyP has been demonstrated by recent molecular studies [9, 13]. Although LyP can progress to CD30+ large cell lymphoma and LyP shows expression of CD30, a t(2;5)(p23;q35), common in primary nodal CD30+ anaplastic large cell lymphomas (ALCL) [23, 24], has not been found in any case of LyP studied so far. The absence of a t(2;5) in LyP could be a useful marker to distinguish LyP from skin lesions often associated with primary nodal CD30+ anaplastic large cell lymphoma, which has a significantly worse prognosis [25].

Katharina Peters is supported by grant Sa 576/1-1 from the Deutsche Forschungsgemeinschaft. M. Kadin is supported by NIH grant CA 54062 and the Beth Israel Pathology Foundation, Inc. We are thankful for the technical assistance of R. Wimpenny and S. York. J. Knoll is supported by NIH grant HD18658 and the Beth Israel Pathology Foundation, Inc.

REFERENCES

- Macaulay WL (1968): Lymphomatoid papulosis: A continuing self-healing eruption, clinically benign-histologically malignant. *Arch Dermatol* 97:23-30.
- Kadin ME, Naso K, Sako D, Said J, Vonderheid E (1985): Lymphomatoid papulosis: a cutaneous proliferation of activated helper T-cells expressing Hodgkin's disease associated antigens. *Am J Pathol* 119:315-325.
- Espinoza CG, Erkman-Balis B, Fenske NA (1985): Lymphomatoid papulosis: a premalignant T cell disorder. *J Am Acad Dermatol* 13:736-743.
- Parks JD, Synovec MS, Masih AS, Braddock SW, Nakamine H, Sanger WG, Harrington DS, Weisenburger DD (1992): Immunophenotypic and genotypic characterization of lymphomatoid papulosis. *J Am Acad Dermatol* 26:968-975.
- Whang-Peng J, Bunn PA, Knutsen T (1982): Clinical implications of cytogenetic studies in cutaneous T-cell lymphoma (CTCL). *Cancer* 50:1539-1553.
- Verallo VW, Fand SB (1969): DNA measurements in lymphomatoid papulosis: Evidence for this new entity. *J Invest Dermatol* 53:51-57.
- Willemze R, Meyer CJLM, Van Vloten WA, Scheffer E (1982): The clinical and histological spectrum of lymphomatoid papulosis. *Br J Dermatol* 107:131-144.
- Seabright M (1971): A rapid banding technique for human chromosomes. *Lancet* 2:971-972.
- Kaudewitz P, Herbst H, Anagnostopoulos I, Eckert F, Braun-Falco O, Stein H (1991): Lymphomatoid papulosis followed by large-cell lymphoma: immunophenotypical and genotypical analysis. *Br J Dermatol* 124:465-469.
- Beljaards RC, Willemze R (1992): The prognosis of patients with lymphomatoid papulosis associated with malignant lymphomas. *Br J Dermatol* 126:596-602.
- Harrington DS, Braddock SW, Blocher KS, Weisenburger DD, Sanger W, Armitage JO (1989): Lymphomatoid papulosis and progression to T cell lymphoma: an immunophenotypic and genotypic analysis. *J Am Acad Dermatol* 21:951-957.
- Davis TH, Morton CC, Miller-Cassman R, Balk SP, Kadin ME (1992): Hodgkin's disease, lymphomatoid papulosis, and cutaneous T-cell lymphoma derived from a common T-cell clone. *N Engl J Med* 326:1115-1122.
- Volkenandt M, Bertino JR, Vittal Shenoy B, Koch OM, Kadin ME (1993): Molecular evidence for a clonal relationship between lymphomatoid papulosis and Ki-1 positive large cell anaplastic lymphoma. *J Dermatologic Science* 6:121-126.
- Verma RS, Macera MJ, Krishnamurty M, Abramson J, Kapelner S, Dosik H (1987): Chromosomal abnormalities in adult T-cell leukemia/lymphoma (ATL). A report of six cases with review of the literature. *J Cancer Res Clin Oncol* 113:192-196.
- Cabanillas F, Pathak S, Trujillo J, Manning J, Katz R, McLaughlin P, Velasquez WS, Hagemester FB, Goodacre A, Cork A, Butler JJ, Freireich EJ (1988): Frequent nonrandom chromosome abnormalities in 27 patient with untreated large cell lymphomas and immunoblastic lymphomas. *Cancer Res* 48:5557-5564.
- Schlegelberger B, Himmler A, Godde E, Grote W, Feller AC, Lenner K (1994): Cytogenetic findings in peripheral T-cell lymphomas as a basis for distinguishing low-grade and high-grade lymphomas. *Blood* 83:505-511.
- Dal Cin P, Aly MS, Delabie J, Ceuppens JL, Van Gool S, Van Damme B, Baert L, Van Poppel H, Van den Berghe H (1992): Trisomy 7 and trisomy 10 characterize subpopulations of tumor-infiltrating lymphocytes in kidney tumors and in the surrounding kidney tissue. *Proc Natl Acad Sci USA* 89:9744-9748.
- Brito-Babapulle V, Matutes E, Parreira L, Catovsky E (1986): Abnormalities of chromosome 7q and TAC expression in T-cell leukemias. *Blood* 67:516-521.
- Schlegelberger B, Weber-Matthiesen K, Himmler A, Bartels H, Sonnen R, Kuse R, Feller AC, Grote W (1993): Cytogenetic findings and results of combined immunophenotyping and karyotyping in Hodgkin's disease. *Leukemia* 8:72-80.
- Speaks SL, Sanger WG, Masih AS, Harrington DS, Hess M, Armitage JO (1992): Recurrent abnormalities of chromosome bands 10q23-25 in non-Hodgkin's lymphoma. *Genes Chrom Cancer* 5:239-243:1992.
- Dube ID, Lu M, Raimondi S, Carroll A, Wu X, Baker J, Hogg D (1990): The TCL3 oncogene is expressed in normal tissue and is dysregulated via recombinase-mediated recombination in leukemic cells from patients with T(10;14). *Blood* 76(Suppl 1):230a.
- Zutter M, Hockett RD, Roberts CW, McGuire EA, Bloomstone J, Morton CC, Deaven LL, Crist WM, Carroll AJ, Korsmeyer SJ (1990): The t(10;14)(q24;q11) of T-cell acute lymphoblastic leukemia juxtaposes the delta T-cell receptor with TCL3, a conserved and activated locus at 10q24. *Proc Natl Acad Sci USA* 87:3161-3165.
- Fischer P, Nacheva E, Mason DY, Sherrington PD, Hoyle C, Hayhoe FG, Karpas A (1988): A Ki-1 (CD30)-positive human cell line (Karpas 299) established from a high-grade non-Hodgkin's lymphoma, showing a 2;5 translocation and rearrangement of the T-cell receptor β -chain gene. *Blood* 72:234-240.
- LeBeau MM, Bitter MA, Larson RA, Doane LA, Ellis ED, Franklin WA, Rubin CM, Kadin ME, Vardiman JW (1989): A recurring chromosomal abnormality in Ki-1 positive anaplastic large cell lymphoma. *Leukemia* 3:866-870.
- DeBruin PC, Beljaards RC, Van Heerde P, Van der Valk P, Noorduyns LA, Van Krieken JHJM, Kluin-Nelemans JC, Willemze R, Meijer CJLM (1993): Differences in clinical behavior and immunophenotype between primary cutaneous and primary nodal anaplastic large cell lymphoma of T-cell or null cell phenotype. *Histopathology* 23:127-135.